HOSPITAL FOR SPECIAL SURGERY

WINTER 2012 | VOLUME 3 | ISSUE 1

Grand Rounds from HSS

MANAGEMENT OF COMPLEX CASES

Authors

Robert L. Buly, MD
Associate Attending Orthopaedic Surgeon
Hospital for Special Surgery
Associate Professor of Orthopaedic Surgery
Weill Cornell Medical College

David L. Helfet, MD
Chief, Orthopaedic Trauma Service
Attending Orthopaedic Surgeon
Hospital for Special Surgery
Professor of Orthopaedic Surgery
Weill Cornell Medical College

Bryan T. Kelly, MD
Co-Director, Center for Hip Preservation
Associate Attending Orthopaedic Surgeon
Hospital for Special Surgery
Associate Professor of Orthopaedic Surgery
Weill Cornell Medical College

Ernest L. Sink, MD
Co-Director, Center for Hip Preservation
Associate Attending Orthopaedic Surgeon
Hospital for Special Surgery
Associate Professor of Orthopaedic Surgery
Weill Cornell Medical College

David S. Wellman, MD
Assistant Attending Orthopaedic Surgeon
Hospital for Special Surgery
Instructor in Orthopaedic Surgery
Weill Cornell Medical College

Riley J. Williams, III, MD
Director of the Institute for Cartilage Repair
Associate Attending Orthopaedic Surgeon
Hospital for Special Surgery
Associate Professor of Orthopaedic Surgery
Weill Cornell Medical College

Co-authors

Gregory G. Klingenstein, MD
Orthopaedic Surgery Fellow
Hip Preservation
Hospital for Special Surgery

Lazaros A. Poultsides MD, MSc, PhD
Orthopaedic Surgery Fellow
Hip Preservation
Hospital for Special Surgery

FROM THE EDITOR



A very important development in orthopaedic surgery with tremendous potential for healthcare benefit is the emerging discipline of joint preservation. Innovations are achieved within an interdisciplinary culture, devising new techniques to diagnose early joint conditions, correct joint mechanics, understand and reverse articular cartilage degeneration and regenerate damaged articular cartilage. The HSS Center for Hip Preservation, directed by Bryan Kelly and Ernest Sink, brings together such a multidisciplinary team, collaborating to diagnose and treat the complex developmental and traumatic conditions that put the hip joint in jeopardy and that ultimately progress to end stage arthritis. Please visit **www.hss.edu/hippain**.

In this volume we present three cases from the Center for Hip Preservation that highlight this innovative interdisciplinary approach. In the first case, Bryan Kelly identifies and arthroscopically resects the anterior inferior iliac spine as a source of disabling hip impingement, restoring a professional football player to exceptional levels of performance. Next, Ernest Sink, Bryan Kelly and Riley Williams perform a surgical hip dislocation to correct femoroacetabular impingement, and restore a large osteochondral lesion on the femoral head using osteochondral allograft transplantation. In the final case, David Wellman, Robert Buly and David Helfet perform staged bilateral periacetabular osteotomies for the surgical treatment of developmental hip dysplasia.

Each case shows very promising early results. The long-term success of these innovative procedures in preventing or minimizing progressive hip degenerative disease has yet to be determined. To this end, as with all conditions and procedures under study at HSS, these cases are entered into patient centered, clinical outcome research registries, applying the essential prospective methodology to develop scientific evidence that will inform and direct the future of joint preservation.

We hope you find these cases to be of interest and the principles presented informative. Comments are always welcome at **complexcases@hss.edu.**

— Edward C. Jones, MD, MA, Assistant Attending Orthopaedic Surgeon

in this issue

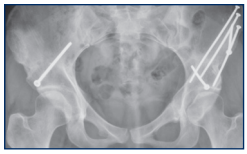

CASE 1

Anterior Inferior Iliac Spine as a Source of Hip Impingement

Case presented by Bryan T. Kelly, MD, and Gregory G. Klingenstein, MD

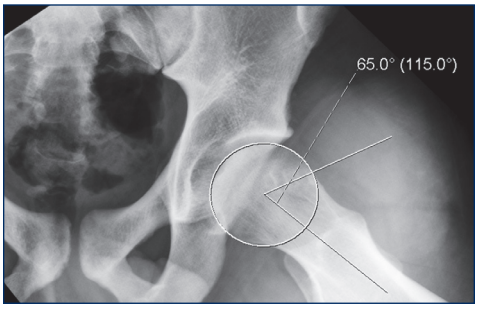

Figure 1: Dunn lateral shows no fracture, but an alpha angle of 65 degrees.

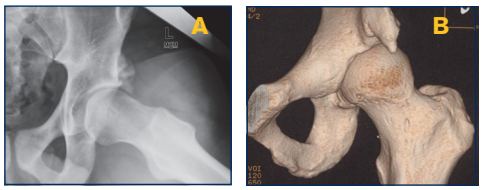

Figure 2: (2A) Frog leg lateral radiograph and (2B) 3D CT reconstruction demonstrate extensive heterotopic ossification in the region of the AIIS and a herniation pit in the anterior head-neck junction; a prime example of subspine impingement.

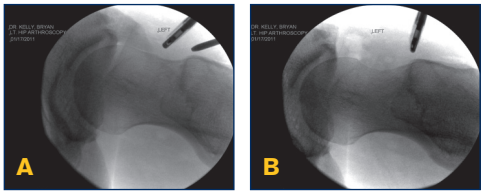

Figure 3: Fluoroscopic images of the heterotopic ossification before and after resection and cam decompression.

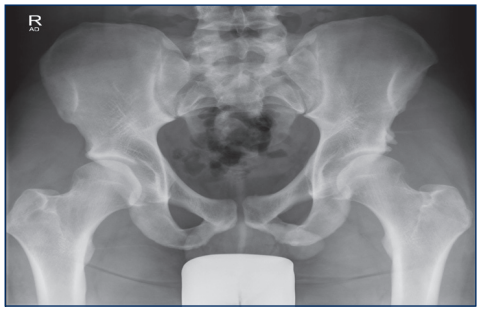

Figure 4: AP pelvis six months after surgery shows adequate subspine decompression, and no reoccurrence of HO.

CASE REPORT: Femoroacetabular impingement (FAI) consists of a conflict between the proximal femur and acetabular rim preventing a normal arc of hip motion (1). Most literature has focused on asphericity of the head-neck junction and deep acetabuli as seen in coxa profunda. Other sources of impingement, such as the anterior inferior iliac spine (AIIS) also have the potential to restrict hip motion (2). We present a case of extra-articular AIIS impingement in a professional athlete.

A 29-year-old professional football player initially felt a "pop" in the anterior aspect of his left hip during a pass rush. The patient experienced pain, was unable to flex his hip against gravity, and was removed from the game. Radiographs did not reveal any trauma, but his alpha angle was elevated at 65º on a Dunn lateral (Figure 1). MRI showed a tear and avulsion of the direct head of the rectus femoris, longitudinal stripping of the reflected head, high signal in the anterior labrum, and a herniation pit in the anterior proximal femur. In summary, the diagnosis was acute traumatic rupture of the rectus femoris in the setting of FAI.

At that time the patient elected non-operative treatment for the rectus tear and FAI. After three weeks he returned to unrestricted activity and, despite persistent mild anterior hip pain, played at a high level for the next two seasons. In 2008, a follow-up X-ray showed extensive heterotopic ossification around the AIIS. He then sustained a bucket handle tear of the left lateral meniscus during the preseason. The meniscus was repaired arthroscopically, but the hip went untreated despite mild to moderate pain.

The patient returned to play the 2009 and 2010 seasons despite worsening left hip pain. Repeat imaging showed further consolidation of the heterotopic ossification. 3D CT reconstruction revealed a large bone mass in the area of the AIIS and a herniation pit in the anterior head-neck junction (Figures 2A and 2B). MRI demonstrated persistent labral injury, as well as multiple herniation pits at the site of impingement. Due to worsening pain, the patient underwent hip arthroscopy with subspine and proximal femoral osteoplasty (Figures 3A and 3B). Intraoperatively, there was no discreet labral detachment, but early chondral delamination was present at the chondrolabral junction. Extensive synovitis and apparent crush injury was seen in the labrum, capsule, and rectus tendon.

Postoperative rehabilitation consisted of 14 days of protected weight-bearing and stationary bicycle for four weeks. Formal supervised PT continued for the first three months. Functional sport-specific rehab started after four weeks, with full return to sport at four months. The player is currently performing without hip symptoms (Figure 4).

DISCUSSION: Femoroacetabular impingement has traditionally been described as either proximal femoral (cam) or acetabular (pincer) deformity. Ganz defined pincer impingement as rim impingement from acetabular retroversion or coxa profunda (1). Recently, extra-articular sources of impingement, such as the AIIS, have been recognized (3). The AIIS is the insertion point for the direct head of the rectus femoris and has variable morphology which may impinge on the femoral neck. In this case, there was a traumatic injury with documented avulsion of the rectus tendon, leading to heterotopic ossification. However, subspine impingement may also present without a discrete injury (3). Symptoms often include pain with straight hip flexion, as opposed to flexion, adduction, and internal rotation seen with intra-articular FAI. Radiographically, distal extension of the AIIS may produce a sclerotic appearance of the anterior acetabular rim. It is our observation that

Continued on page 5

CASE 2

Surgical Hip Dislocation, Osteochondroplasty and Osteochondral Allograft Transplantation to Correct FAI and a Large Osteochondral Lesion of the Femoral Head

Case presented by Ernest L. Sink, MD, Bryan T. Kelly, MD, Riley J. Williams, III, MD, and Lazaros A. Poultsides, MD, MSc, PhD

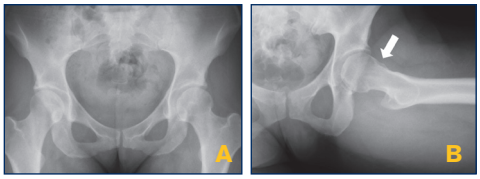

Figure 1: Preoperative anteroposterior (A) and lateral elongated view (B) demonstrating joint congruity, no cross-over sign, a significant posterior wall, a grade 1 Tonnis classification and loss of the anterior head-neck offset (arrow).

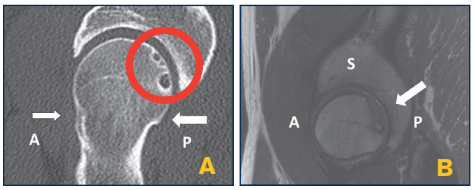

Figure 2: CT scan (2A) showing early osteoarthritis with subchondral cystic changes (circle) involving the posterior-superior head and cam deformity in the anterolateral (thin arrow) and posterosuperior (thick arrow) head neck junction. MRI sagittal view (2B) demonstrating an osteochondral lesion of the posterior-superior margin of the femoral head with cystic resorption of subchondral bone and basilar delamination of cartilage with separation at tidemark (arrow). A: anterior; P: posterior; S: superior

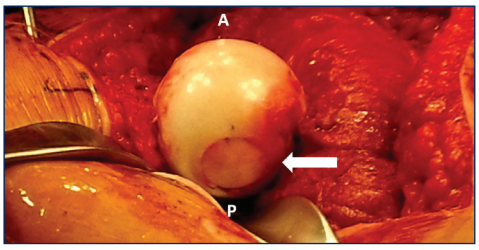

Figure 3: Intraoperative picture showing the restoration of the femoral head sphericity and anatomic contour after the osteochondral plug was placed (arrow). A: anterior; P: posterior

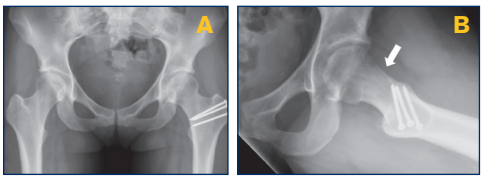

Figure 4: Postoperative anteroposterior (4A) and lateral elongated view (4B) demonstrating union of the trochanteric osteotomy, incorporation of the osteochondral allograft and restoration of the anterior offset of the head-neck junction (arrow).

CASE REPORT: This 25-year-old female presented at HSS with chronic left hip and groin pain. A former college soccer player and runner, she described her symptoms as anterior and posterior pain, weakness, and stiffness, aggravated with physical activity and improved with rest. She denied night pain. There was no specific traumatic event related to her symptoms. One year prior to her initial presentation, the patient underwent arthroscopic labral repair and cam decompression at an outside institution. She had some early postoperative relief but after three months of physical therapy her symptoms returned. Upon presentation to our clinic, she walked with an antalgic gait, had a negative Trendelenburg sign and her leg lengths were equal. Physical examination of the left hip revealed 105° of flexion, 25° of abduction, and 10° of adduction; at 90° of flexion, she had 10° of internal and 10° of external rotation. Provocative pain testing revealed pain in the impingement, subspine (straight flexion), apprehension (anterior pain with extension and external rotation), and posterior impingement (posterior pain with extension and external rotation). Her neurovascular exam was normal.

Plain radiographs (AP standing and lateral elongated view) demonstrated good joint congruity, negative cross-over sign, deficiency of femoral head-neck offset and grade 1 Tonnis classification (Figure 1A, B). CT scan of the left hip revealed subchondral cystic change involving the posterior-superior head and residual cam deformity in the anterolateral and posterosuperior head-neck junction (Figure 2A). Anterior and posterior α-angles were 57° and 56°, respectively; the coronal center-edge angle was 31° and femoral anteversion was 9°. MRI showed an osteochondral lesion of the posterior-superior margin of the femoral head with cystic resorption of subchondral bone and basilar delamination of cartilage with separation at the tidemark (Figure 2B). Intra-articular injection of anesthetic and steroid provided temporary relief of symptoms.

It was decided to proceed with surgical dislocation of the left hip in order to evaluate the intrarticular and extrarticular pathology and address the residual cam deformity and the associated osteochondral lesion. The hip joint was exposed using the Gibson modification and a trochanteric osteotomy. When the joint was taken through full range of motion, impingement was noted at 60° of flexion and any internal rotation, confirming our findings at physical examination. Bony prominence was noted at the anterior, superior, anterolateral and superolateral aspects of the head-neck junction. The hip was dislocated anteriorly giving exposure of the femoral head and acetabulum.

Addressing the acetabulum, capsulo-labral scarring at the 1 to 3 o'clock position was debrided, preserving a stable rim of remaining labrum. The space between the anterior inferior iliac spine and the rim was decompressed. A contrecoup lesion was noted with mild cartilage wear in the posterior aspect of the horseshoe. In addition, the ligamentum teres was found to be inflamed and scarred. These findings confirmed the mechanism of anterior impingement and subsequent posterior subluxation of the femoral head. A cartilage flap, which was circular and approximately 20mm in diameter, was found at the posterosuperior aspect of the femoral head, and was debrided to expose the underlying bone. While a fresh osteochondral allograft (distal femur) plug was prepared, an osteochondroplasty was performed extending to the intertrochanteric line including the anterior facet. The press-fit dowel osteochondral plug restored the femoral head sphericity and anatomic contour (Figure 3); templates confirmed offset restoration. The hip was reduced and found to be stable and impingement-free through a full range of motion, including full flexion and 50° of internal rotation.

Weight bearing was limited to toe-touch for six weeks and then progressed as

Continued on page 5

CASE 3

Staged Bilateral Periacetabular Osteotomies for the Surgical Treatment of Hip Dysplasia

Case presented by David S. Wellman, MD, Robert L. Buly, MD, and David L. Helfet, MD

Figure 1: (A) False profile radiographic view of the right hip, (B) Anteroposterior (AP), (C) false profile radiographic view of the left hip, illustrating bilateral hip dysplasia.

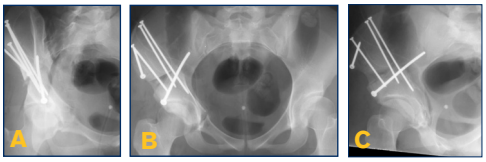

Figure 2: Immediate postoperative (A) obturator oblique (B) AP, and (C) iliac oblique radiographic views following right PAO demonstrating improved coverage of the femoral head and acceptable hardware placement.

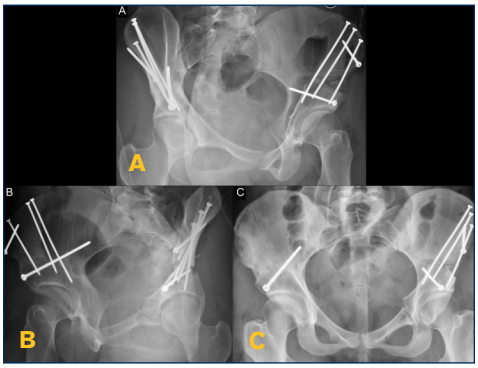

Figure 3: (A, B) Judet radiographs following left PAO and (C) final postoperative AP following partial hardware removal (right acetabulum). Radiographs demonstrate improved coverage of the femoral head and acceptable hardware placement.

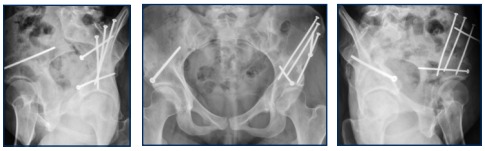

Figure 4: Most recent radiographs, six months following left PAO and four years following right PAO), demonstrate healed osteotomies, maintenance of fixation and improved femoral head coverage.

CASE REPORT: An 18-year-old female presented to HSS complaining of worsening hip pain over the past five years, especially with sports and ballet. Her exam displayed 120° of flexion, 40° of internal rotation, and 25° of external rotation bilaterally. She had pain with internal rotation, flexion, and adduction in both hips. Radiographs revealed center-edge angles less than 20° on both AP and "false profile" lateral views, consistent with decreased femoral head coverage (Figure 1). There was no radiographic evidence of hip impingement. An MRI scan was performed, which displayed a torn labrum. These findings convinced the treating surgeons to recommend labral debridement and a pelvic osteotomy to improve femoral head coverage.

After arthroscopic labral debridement, a Bernese periacetabular osteotomy was performed in the supine position through an anterior Smith-Petersen approach. An osteotomy of the anterior superior iliac spine was performed, allowing mobilization of the sartorius muscle. Osteotomies were then made in the ischium, pubis, and ilium, protecting the posterior column of the pelvis. Following positioning of the acetabular fragment to provide adequate coverage of the femoral head, fixation was obtained with screws (Figure 2).

Postoperatively, the patient was maintained at 20% weight bearing (six weeks) with no bracing or range of motion restrictions. At three months after her right PAO, the patient had achieved radiographic union, resolution of right hip pain, and return to pre-injury activities.

At 3.5 years after her right hip operation, she elected to have a left hip PAO performed (along with partial hardware removal on the right) for worsening left hip pain (Figure 3). She most recently presented at six months following the left PAO with pain free (bilateral) flexion to 115°, 30° of internal rotation, 50° of external rotation, 40° of abduction, and 30° of adduction. She has currently returned to all previous activities, including dancing. Radiographs demonstrate union of the osteotomy sites, maintenance of fixation and joint space, and improved femoral head coverage (Figure 4).

DISCUSSION: In developmental dysplasia of the hip (DDH), point loading occurs at the edge of the steep acetabulum, while normal hips display more equal force distribution throughout the dome (1). It is estimated that dysplasia has a role in 20% to 50% of adult hip degeneration cases (2). Once irreversible cartilage damage has occurred, patients are left with few reliable surgical options other than joint arthroplasty.

From the anteroposterior radiographic views, the center-edge angle of Wiberg can be measured. Values of less than 15° are regarded as moderate dysplasia and values less than 5° are graded as severe (3). Both of these categories have been associated with later development of hip arthritis (4).

The goals of surgery are to re-direct the acetabulum to optimize the force distribution throughout the dome. The Bernese group recently published their 20-year follow-up data after PAO and found that hips with low osteoarthritis scores pre-operatively were seen to have survivorship of 75% (5). They identified six risk factors for failure: "(1) increased age at surgery, (2) lower preoperative Merle d'Aubigné and Postel score, (3) positive preoperative anterior impingement test, (4) preoperative limp, (5) preoperative increased OA score (Tönnis), and (6) postoperative increased extrusion index" (5). PAO appears effective in properly selected patients with results superior to the natural history of the disease (5).

The Bernese PAO was chosen in the current patient for several reasons. As her triradiate cartilage had closed, there was no risk to the growth of the pelvis after associated osteotomies.

Continued on page 6

CASE 1 CONTINUED

a large portion of cross-over signs on AP pelvis X-rays represent the subspine region, not a retroverted acetabulum as previously thought.

This case is an example of how altered hip mechanics in FAI may lead to other injuries in the pelvis and lower extremities (4). At the time of initial injury, this football player already had indirect signs of FAI on MRI: anterior superior labral injury and a herniation pit in the anterior head-neck junction. Proximal femur deformity was confirmed by the 3D CT reconstruction. We hypothesize that limited hip ROM from FAI predisposed the patient to rectus avulsion, which then ossified, creating subspine impingement. Further restriction of hip motion then contributed to the lateral meniscal tear. Since receiving arthroscopic treatment for FAI, the player has returned to playing in the NFL and has avoided further career threatening injuries. ■

REFERENCES:

1. Ganz R, Parvizi J, Beck M, Leunig M, Nötzli H, Siebenrock KA. Femoroacetabular impingement: a cause for osteoarthritis of the hip. *Clin Orthop Relat Res.* 2003 Dec;(417):112-20.
2. Pan H, Kawanabe K, Akiyama H, Goto K, Onishi E, Nakamura T. Operative treatment of hip impingement caused by hypertrophy of the anterior inferior iliac spine. *J Bone Joint Surg Br.* 2008 May;90(5):677-9.
3. Larson CM, Kelly BT, Stone RM. Making a case for anterior inferior iliac spine/subspine hip impingement: three representative case reports and proposed concept. *Arthroscopy.* 2011 Dec;27(12):1732-7.
4. Nho SJ, Magennis EM, Singh CK, Kelly BT. Outcomes after the arthroscopic treatment of femoroacetabular impingement in a mixed group of high-level athletes. *Am J Sports Med.* 2011 Jul;39 Suppl:14S-9S.

AUTHOR DISCLOSURES:

Bryan T. Kelly, MD, does not have a financial interest or relationship with the manufacturers of products or services.

Gregory G. Klingenstein, MD, does not have a financial interest or relationship with the manufacturers of products or services.

CASE 2 CONTINUED

tolerated. She returned for her three month follow-up and was walking pain free (mild limp) without an assistive device. She had mild pain with impingement test and straight flexion exceeding 110°. Internal and external rotation was 20° and 30°, respectively. Her follow-up X-ray demonstrated union of the trochanteric osteotomy, incorporation of the osteochondral allograft and restoration of the anterior offset of the head-neck junction (Figure 4A, B).

DISCUSSION: Although hip arthroscopy and surgical hip dislocation have been described as effective approaches to manage femoroacetabular impingement (FAI), multiple treatment options have been developed for cartilage repair. These procedures have evolved from arthroscopic lavage and debridement, to marrow stimulation techniques and more recently to autogenous chondrocyte implantation and osteochondral autograft and allograft transplants.

Osteochondral mosaicplasty-autograft (OATS) combined with surgical dislocation of the hip have shown promising results (1, 2). In a series of 10 young adults with osteochondral lesions of the femoral head (1), OATS demonstrated improvement in clinical scores and global range of motion with a mean follow-up of 29.2 months (20-39). Radiologic evaluation (plain X-ray and CT) at six months revealed incorporation of the osteochondral plugs with a cover of intact cartilage. Similarly, Nam et al (2) reported two cases of traumatic hip dislocation, with chondral defects successfully treated with OATS procedures, incorporating osteochondral plugs from the ipsilateral knee and inferior head, respectively. At a follow-up of greater than one and five years respectively, MRI demonstrated good autograft incorporation with maintenance of articular surface congruity and clinical improvement in both patients.

Resurfacing of the femoral head with fresh osteochondral allograft has shown good results in a series of 21 avascular necrosis patients with segmental collapse of the head, especially in the non-steroid-treated patients (80% success rate) with a follow-up ranging from 9 to 63 months (3). Although osteochondral allograft transplantation has wide application in oncologic patients, two case reports of femoral head fracture-dislocation (4, 5) revealed that both patients had significant clinical improvement with a follow-up of four years (4) and one year (5), respectively, despite the MRI and radiographic evidence of progressive hip arthritis in one case (4).

This case illustrates the challenge of managing patients with FAI with associated osteochondral lesion of the femoral head. Preoperative planning is of paramount importance. In this case, surgical hip dislocation was chosen as the appropriate surgical approach with the advantage of providing great exposure to the hip joint while preserving its vasculature, and facilitating the concomitant management of FAI and cartilage defect. Osteochondral allograft transplantation seems to be a promising treatment modality in such cases. However, long term outcomes regarding graft incorporation, viability and symptomatic progression to osteoarthritis are yet to be determined. ■

REFERENCES:

1. Girard J, Roumazeille T, Sakr M, Migaud H. Osteochondral mosaicplasty of the femoral head. *Hip Int.* 2011 Sep;21(5):542-8.
2. Nam D, Shindle MK, Buly RL, Kelly BT, Lorich DG. Traumatic osteochondral injury of the femoral head treated by mosaicplasty: a report of two cases. *HSS J.* 2010 Sep;6(2):228-34.
3. Meyers MH. Resurfacing of the femoral head with fresh osteochondral allografts. Long-term results. *Clin Orthop Relat Res.* 1985 Jul-Aug;(197):111-4.
4. Nousiainen MT, Sen MK, Mintz DN, Lorich D, Paul O, Buly RL, Helfet DL. The use of osteochondral allograft in the treatment of a severe femoral head fracture. *J Orthop Trauma.* 2010 Feb;24(2):120-4.
5. Evans KN, Providence BC. Case report: Fresh-stored osteochondral allograft for treatment of osteochondritis dissecans of the femoral head. *Clin Orthop Relat Res.* 2010 Feb;468(2):613-8.

AUTHOR DISCLOSURES:

Bryan T. Kelly, MD, does not have a financial interest or relationship with the manufacturers of products or services.

Ernest L. Sink, MD, does not have a financial interest or relationship with the manufacturers of products or services.

Riley J. Williams, III, MD, does not have a financial interest or relationship with the manufacturers of products or services.

Lazaros A. Poultsides, MD, MSc, PhD, does not have a financial interest or relationship with the manufacturers of products or services.

HOSPITAL
FOR
**SPECIAL
SURGERY**

535 East 70th Street
New York, NY 10021
www.hss.edu/complexcases

CASE 3 CONTINUED

By adhering to the techniques of the Bernese group, the posterior column was maintained after completion of the osteotomy, allowing for extensive freedom of acetabular repositioning while maintaining the overall pelvic stability (6); this allowed less patient restrictions in the postoperative period and advanced rehabilitation. In the presented case, our patient was able to return to pain-free activity with a potentially reduced risk of late development of bilateral hip arthritis. ■

AUTHOR DISCLOSURES:

Robert L. Buly, MD, does not have a financial interest or relationship with the manufacturers of products or services.

David L. Helfet, MD, does not have a financial interest or relationship with the manufacturers of products or services.

David S. Wellman, MD, does not have a financial interest or relationship with the manufacturers of products or services.

REFERENCES:

1. Gillingham BL, Sanchez AA, Wenger DR. Pelvic osteotomies for the treatment of hip dysplasia in children and young adults. *J Am Acad Orthop Surg* 1999 Sep-Oct;7(5):325-37.
2. Weinstein SL. Natural history of congenital hip dislocation (CDH) and hip dysplasia. *Clin Orthop Relat Res* 1987 Dec;(225)(225):62-76.
3. Jessel RH, Zurakowski D, Zilkens C, Burstein D, Gray ML, Kim YJ. Radiographic and patient factors associated with pre-radiographic osteoarthritis in hip dysplasia. *J Bone Joint Surg Am* 2009 May;91(5): 1120-9.
4. Murphy SB, Ganz R, Muller ME. The prognosis in untreated dysplasia of the hip. A study of radiographic factors that predict the outcome. *J Bone Joint Surg Am* 1995 Jul;77(7):985-9.
5. Steppacher SD, Tannast M, Ganz R, Siebenrock KA. Mean 20-year followup of Bernese periacetabular osteotomy. *Clin Orthop Relat Res* 2008 Jul;466(7): 1633-44.
6. Siebenrock KA, Leunig M, Ganz R. Periacetabular osteotomy: the Bernese experience. *Instr Course Lect* 2001;50:239-45.

DESIGN/PRODUCTION:
Marcia Ennis | Director, Education Publications & Communications

Hospital for Special Surgery is an affiliate of NewYork-Presbyterian Healthcare System and Weill Cornell Medical College.

Each author certifies that Hospital for Special Surgery has approved the reporting of this case and that all investigations were conducted in conformity with ethical principles of research.